



Office: (210) 714-2488
Fax: (210) 714-2490
team@SADentalTeam.com
www.SADentalTeam.com
8706 Fredericksburg Road, Suite 104
San Antonio, TX 78240

New Patient Examination and Completed Treatment (Example)

Patient Name: Indiana Jones; Date of Birth: 01/01/2010

Dear Dr. Henry Jones:

Thank you for referring Indiana to San Antonio Dental Team. My name is Dr. Ketan Sukkawala, DDS, and I was the treating dentist for Indiana today.

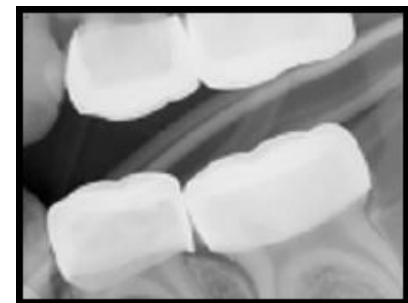
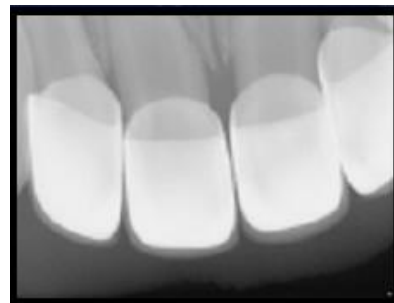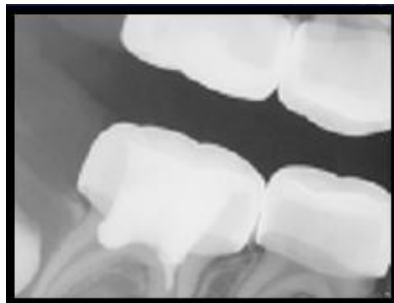
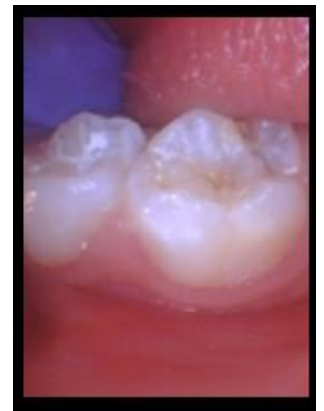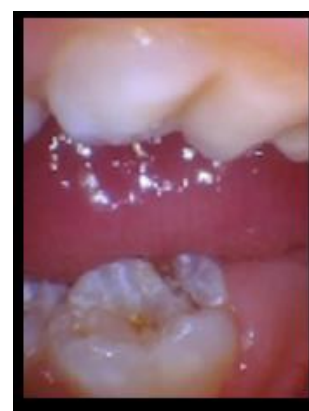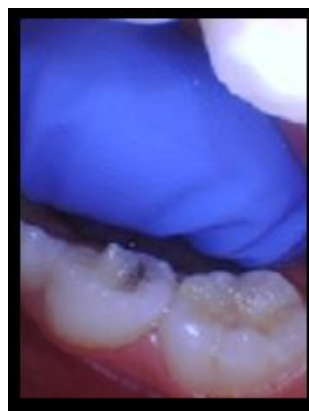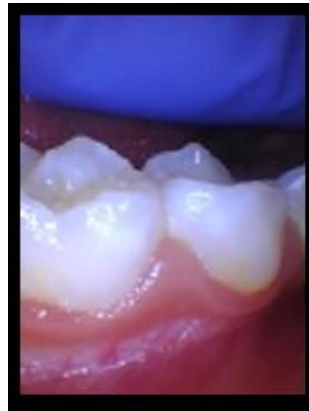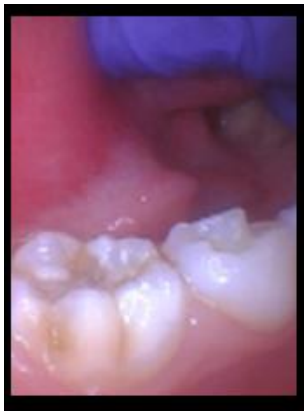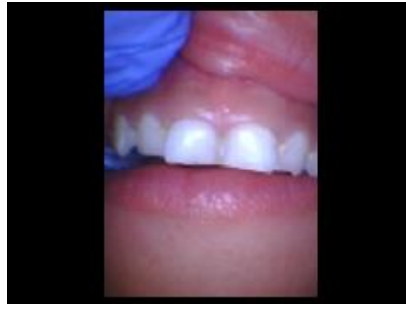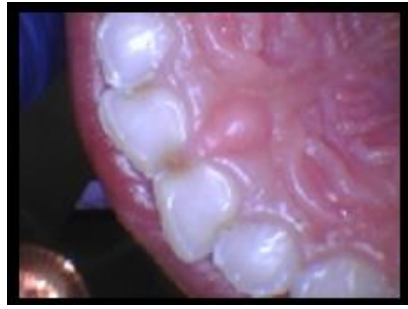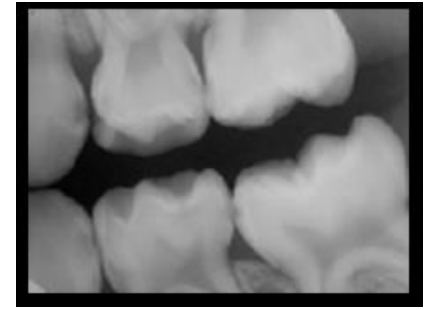
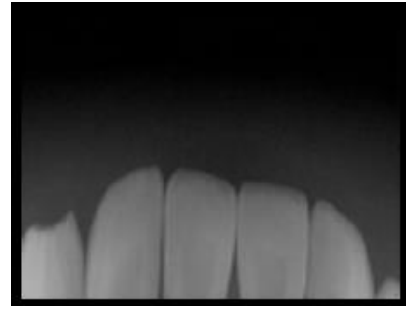
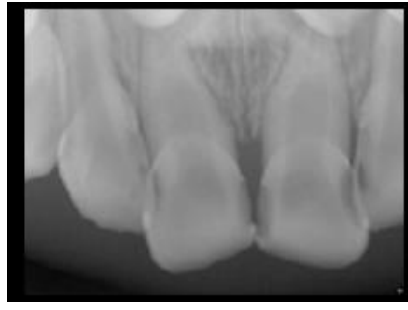
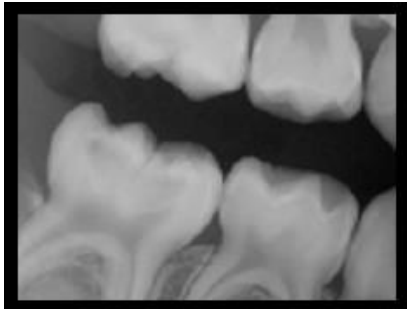
Chief complaint: symptomatic caries

Clinical and Radiographic Examination: once the patient was under general anesthesia, I obtained a complete set of radiographs and intraoral pictures. I performed a prophylaxis in order to accurately form a diagnosis. The subsequent comprehensive exam revealed treatable conditions addressed in the attached list of procedures. General anesthesia was the appropriate option for Indiana. The procedure went very smoothly and recovery was without incident. I had a thorough post-operative discussion with Indiana's parents after the procedure to answer their questions and give post-operative instructions.

If you have any questions at all, please call me any time at (210) 714-2488.

Sincerely,
Ketan Sukkawala, DDS
San Antonio Dental Team

Enclosures: radiographs, intraoral photos, tooth chart, and procedures performed



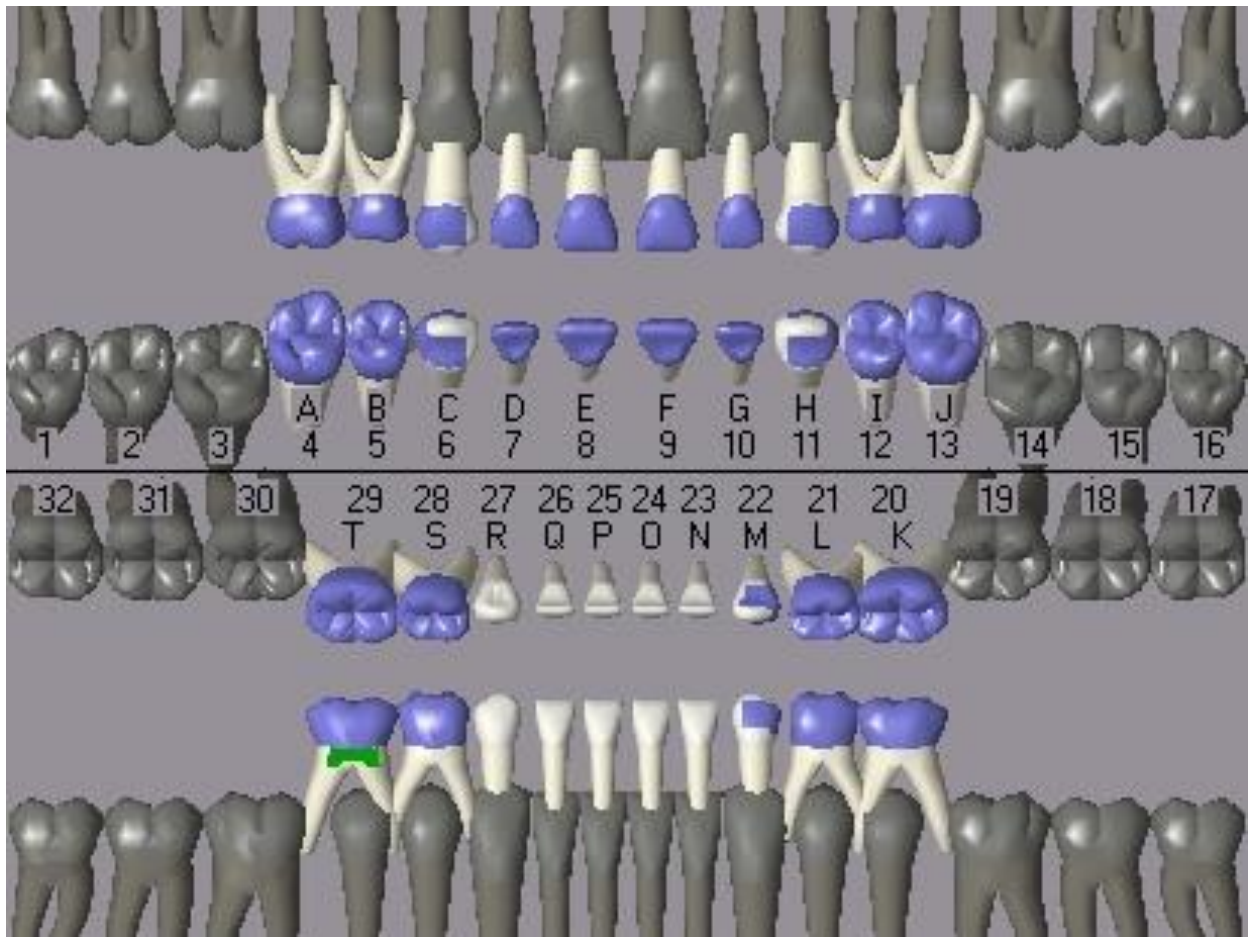


Chart Progress Notes
Indiana Jones

Date	Th	Surf	Dx	Description
3/11/2015				Comprehensive oral evaluation
3/11/2015				Bitewings - two radiographic images
3/11/2015				Prophylaxis - child
3/11/2015				Topical application of fluoride
3/11/2015	A		C	Prefabricated stainless steel crown - primary tooth
3/11/2015	B		C	Prefabricated stainless steel crown - primary tooth
3/11/2015	C	DFL	C	Composite - Three-Surface, Anterior, Primary
3/11/2015	D		C	Prefabricated stainless steel crown - primary tooth
3/11/2015	E			Intraoral - periapical first radiographic image
3/11/2015	E			Prefabricated stainless steel crown - primary tooth
3/11/2015	F			Prefabricated stainless steel crown - primary tooth
3/11/2015	G			Prefabricated stainless steel crown - primary tooth
3/11/2015	H	DFL		Composite - Three-Surface, Anterior, Primary
3/11/2015	I			Prefabricated stainless steel crown - primary tooth
3/11/2015	J			Prefabricated stainless steel crown - primary tooth
3/11/2015	K			Prefabricated stainless steel crown - primary tooth
3/11/2015	L			Prefabricated stainless steel crown - primary tooth
3/11/2015	M	DFL		Composite - Three-Surface, Anterior, Primary
3/11/2015	O			Intraoral - periapical each additional radiographic image
3/11/2015	S			Prefabricated stainless steel crown - primary tooth
3/11/2015	T			Prefabricated stainless steel crown - primary tooth
3/11/2015	T			Therapeutic pulpotomy (excluding final restoration) - removal of pulp coronal to the dentinocemental junction and application of medicament